




Ceka Extracoronary Attachments – Red & Blue System

Benefits:

- The red and blue systems provide the convenience of directly casting the female with the abutment crown(s)
- Select the **RED** system for casting **precious** or **semi-precious** alloys
- Select the **BLUE** system for casting **non-precious** alloys

Female Selection and Positioning



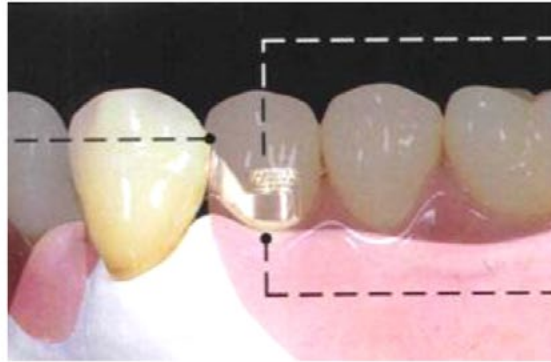
The angled Ceka Revax female provides for excellent oral hygiene and additional space for the removable prosthesis.

The plastic pattern may be adapted to fit to the individual abutment to tissue position.

As shown, the crown position and contour, in combination with the ridge anatomy, determine the selection and adaptation of the female profile.

Position with respect to the abutment crown.

The connection should be immediately below the natural contact zone formed by the marginal ridges.



Position with respect to the first tooth of the removable prosthesis.

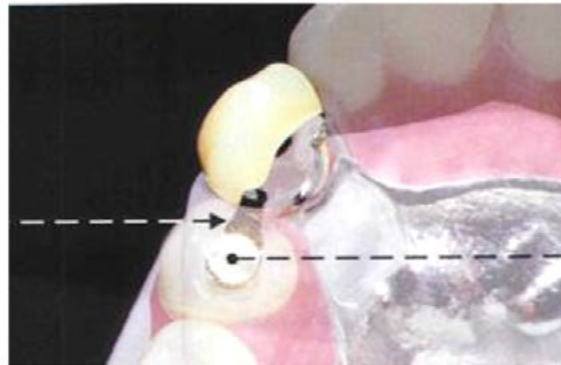
The female should be positioned exactly in the center of the first tooth of the removable prosthesis.

Position with respect to the gingival.

Position the female in light tissue contact for best tissue response and increased interocclusal space.

Esthetic Position.

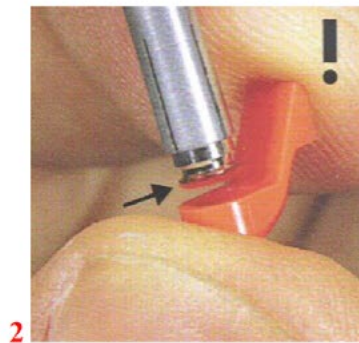
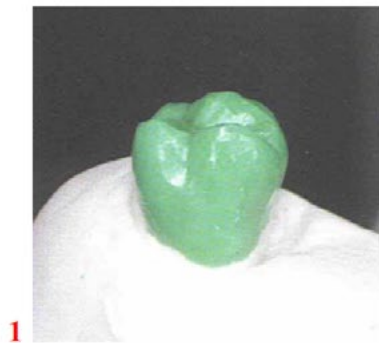The connecting arm is narrowed buccally to maintain a harmonious transition to the first tooth of the removable prosthesis.



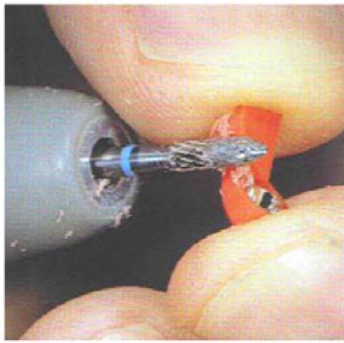
Position with respect to the alveolar ridge.

Position the female towards the center of the ridge.


Red (IRAX) and Blue (Noprax) Systems




Determine the path of insertion and the natural contact point (**FIG 1**). Use the REP2/5 mandrel. When assembling the cast-to female, the **RED/BLUE marking must be DOWN** (**FIG 2**). Select the correct plastic profile, and adapt it to the abutment crown and tissue (**FIG 3**). Please discard the extra plastic patterns, as they are free.



4

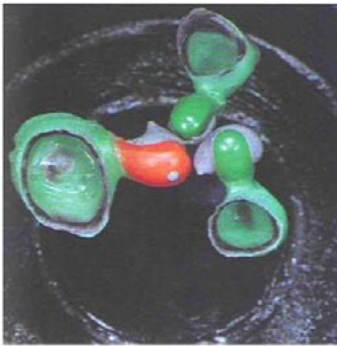


5

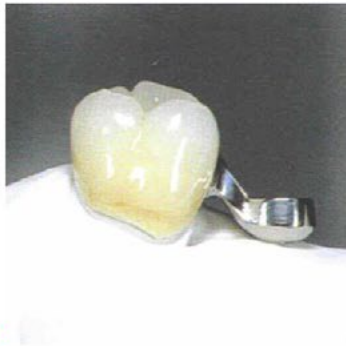


6

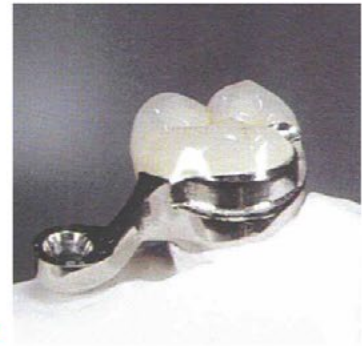Only the inclined arm may be reduced (FIG 4). Never grind the female! To attain passive gingival contact, the model may be slightly trimmed underneath the female keeper (FIG 5). The milled shoulder lies close but clear of the gingiva (FIG 6). A milled 90° shoulder for a lingual arm provides stability, axial loading, easy insertion, and reduced wear



7



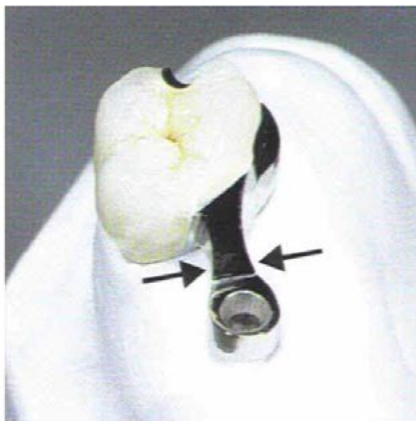
8



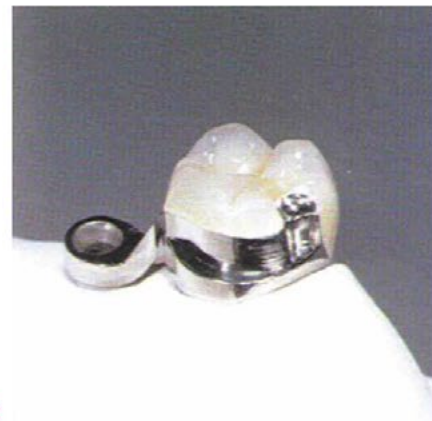9

The small opening on the tissue side of the female facilitates investing. A two-stage investing procedure is recommended. Allow the initial investment to set for 30 minutes (FIG 7). Make sure to wet the initial investment after bench set prior to adding new investment. **NEVER SANDBLAST THE FEMALE, EVEN WHEN REMOVING INVESTMENT!** Preat recommends either bead blasting, shell blasting (neither of these methods will abrade the metal), or chemically removing the investment. Fiberglass pencils are super for removing investment from small, difficult to reach areas.

Maintain anatomical features and light tissue contact. The open embrasure and highly polished tissue side proved for good hygiene (FIG 8). The attachment female and milled shoulder provide for a compatible path of insertion (FIG 9).



10



12

The reduction of the inclined arm (arrows) of the female eliminates buccolingual over-contouring of the removable prosthesis (FIG 10). When possible, the lingual bracing arm extends to an occlusal rest (FIG 11).

Male Pin Retention Cap Options

The Acrylic Retention Technique



The Solder Retention Technique



The Spacer (bonding) Retention Technique

