

Anas Aloum, BDS, FACP<sup>1</sup>  
Omar Aloum, BDS<sup>2</sup>  
Ahmad Al-Jazairi, BDS<sup>3</sup>  
Salah Bagdadi, MDT<sup>4</sup>  
Jamal Ghafari, CDT<sup>5</sup>  
Winston Chee, DDS, FACP<sup>6</sup>

---

<sup>1</sup>Prosthodontist, American Board Certified; Private Practice and Medical Director, HIKMA Medical Center, Abu Dhabi, UAE.

<sup>2</sup>Private Practice and CEO, HIKMA Medical Center, Abu Dhabi, UAE.

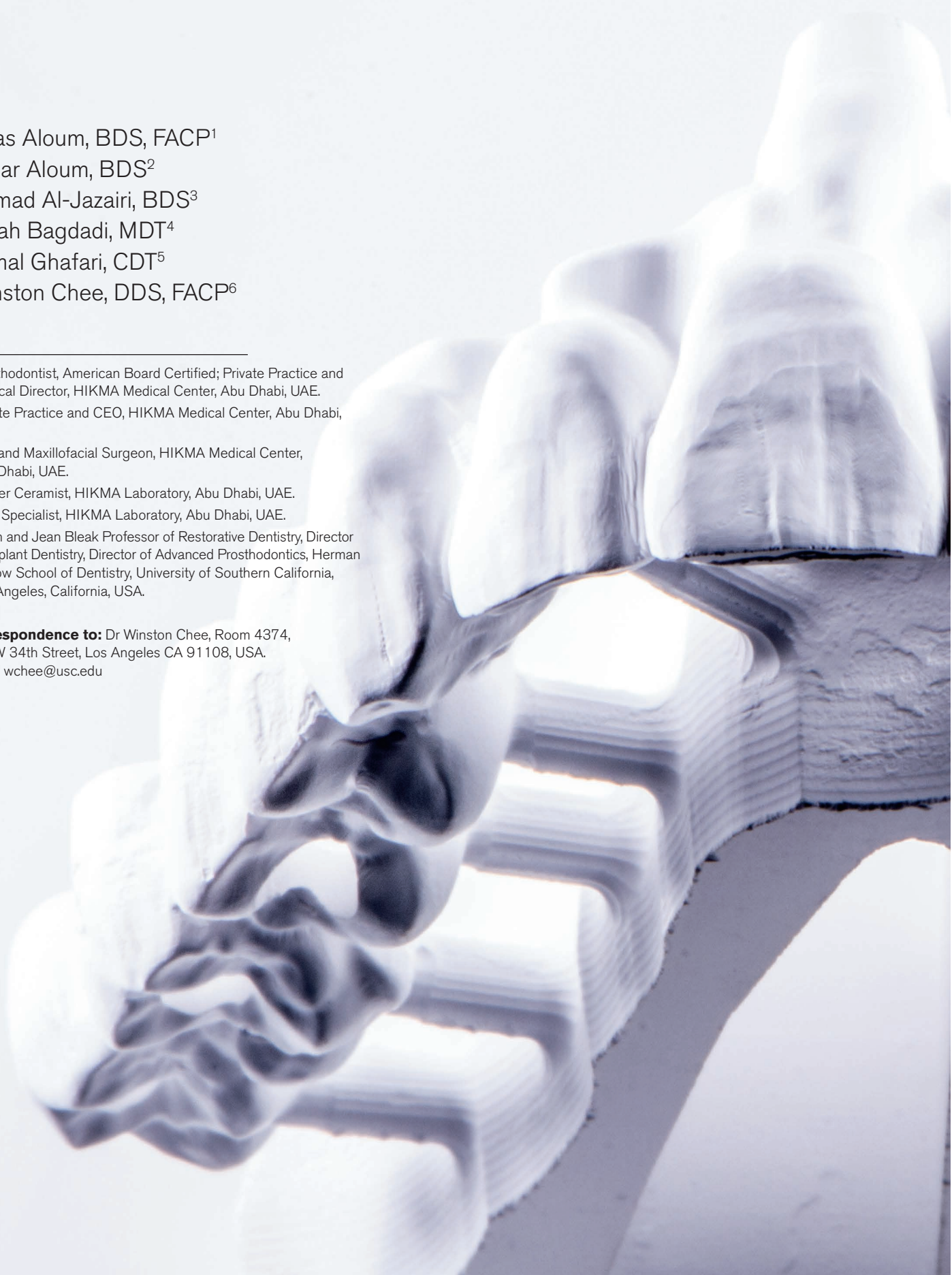
<sup>3</sup>Oral and Maxillofacial Surgeon, HIKMA Medical Center, Abu Dhabi, UAE.

<sup>4</sup>Master Ceramist, HIKMA Laboratory, Abu Dhabi, UAE.


<sup>5</sup>CAD Specialist, HIKMA Laboratory, Abu Dhabi, UAE.

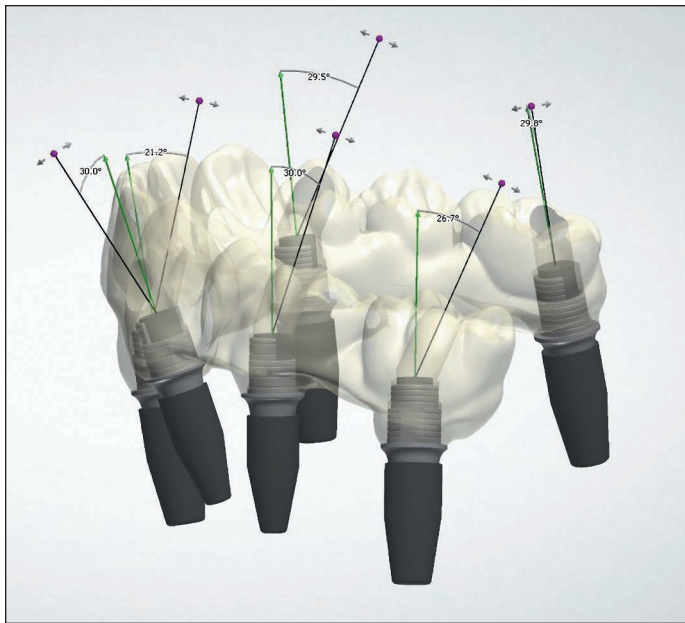
<sup>6</sup>Ralph and Jean Bleak Professor of Restorative Dentistry, Director of Implant Dentistry, Director of Advanced Prosthodontics, Herman Ostrow School of Dentistry, University of Southern California, Los Angeles, California, USA.

**Correspondence to:** Dr Winston Chee, Room 4374,  
925 W 34th Street, Los Angeles CA 91108, USA.  
Email: wchee@usc.edu



# Achieving Esthetics, Function, and Retrievability with Implant-Supported Monolithic Zirconia Restorations While Minimizing Surgical Interventions





**Fig 1** Full arch in the computer-aided design (CAD) phase. Note the different angles of the implants, especially in the anterior region. They are labially placed in accordance with the anatomy of the maxilla as it converges apically.

**L**ong-term maintenance is an important part of being a provider of implant-supported restorations; both biologic and biomechanical aspects of postinsertion care must be addressed. Common biologic complications include retention of excess cement with cemented restorations and associated peri-implant disease. Common biomechanical complications are loosening of screws and breakage of restorations or components.

Implant-supported restorations can be attached to implants with screws or can be cemented to abutments, which in turn are secured to implants with screws. Screw-retained restorations should be the preferred way to attach implant-supported restorations for reasons of retrievability, ease of delivery, ease of maintenance, and elimination of excess cement trapping that plagues cement-retained implant-supported restorations.<sup>1-12</sup>

Placing implants to allow screw retention can be challenging, as implant positions can be severely limited by the presenting anatomy of the ridge or by anatomical structures that impede the placement of implants in the proper trajectory. Implant position is especially impacted in the anterior maxilla.<sup>12-16</sup> The maxillary arch resorbs superiorly and palatally following tooth extraction; in the anterior maxilla, the horizontal bone resorption is almost twice as pronounced as vertical resorption (Fig 1).

## THINKING OUT OF THE BOX

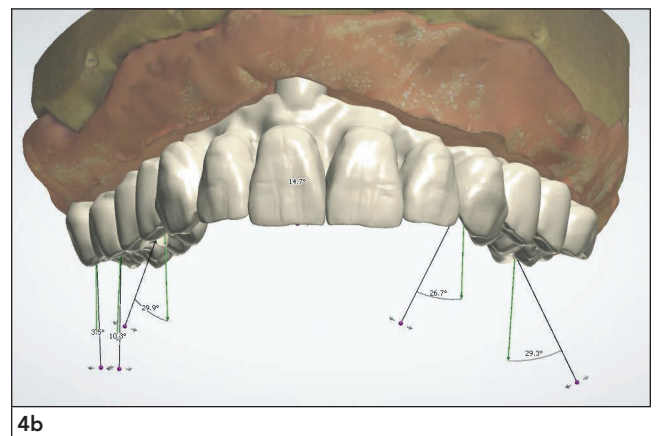
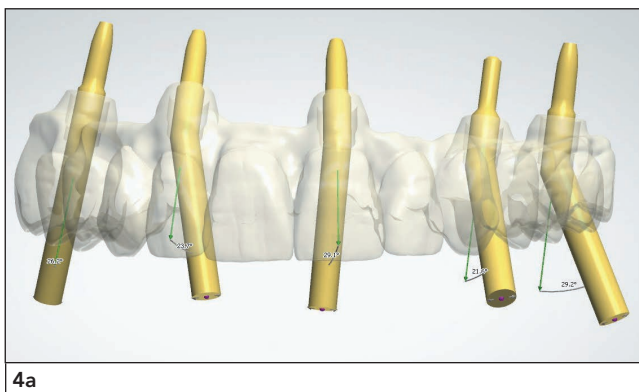
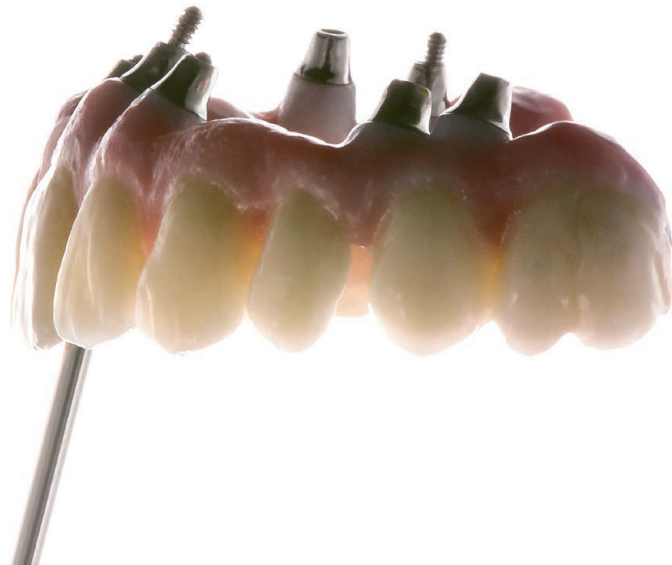This article describes an abutment (Dynamic Abutment, Dynamic Abutment Solutions)<sup>16</sup> that allows deviation to the axis of the implant by up to 30 degrees and its use in conjunction with monolithic zirconia restorations. The nonaxial engagement of the retaining screw is facilitated by a screwdriver with a hexobular driver tip that corresponds to the design of the screw. This allows for a change in the screw access to exit the occlusal area in the posterior and the cingulum area in the anterior for implants placed with inclinations that would normally cause screw access to be in unsuitable positions due to the anatomy of the residual ridge (Figs 2a and 2b). Implants placed in extracted sites are often placed engaging the palatal wall and therefore become facially inclined (Figs 3 and 4). Moreover, when restoring full arches, the need for grafting is reduced and fabricating prostheses that are screw retained becomes technically easier. One of the main advantages of this system is the elimination of pre-angled abutments to alter screw access. Use of abutments that allow an angle change and screw-retention abutments reduce the amount of restorative space available, reduce the amount of submucosal area that is available to hide implant components, and introduce another set of screws that are



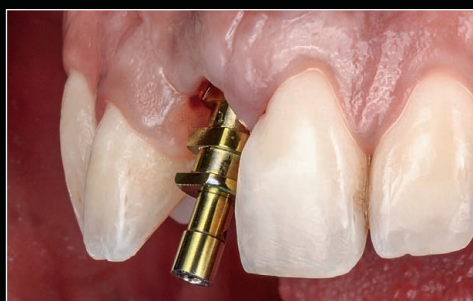
**Figs 2a and 2b** Design of the screw and corresponding screwdriver allows engagement and torquing of the screw up to 30 N/cm in 30-degree rotation. The titanium base can be luted to the zirconia supra-structure, allowing the CAD/CAM prosthesis to be screw retained. The variances in angulation to the axis of the implant are designed in the CAD software.



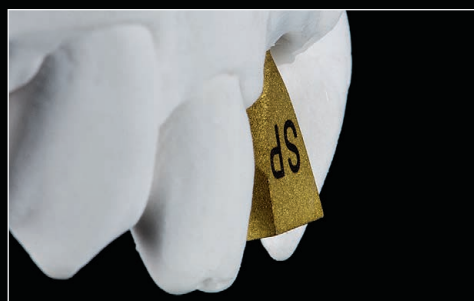**Fig 3** Full-arch screw-retained implant-supported prosthesis. Note the different axes of the screw access relative to the implant. The implants were placed labially due to anatomical constraints. A full-contour translucent zirconia was machined with the angle changes managed during the CAD phase.



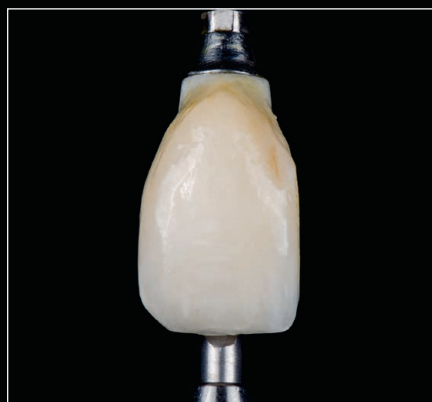**Figs 4a and 4b** Screen captures of CAD of a full-arch restoration using the dynamic abutment and full tooth anatomy library. Note the change in the axial exit of the screw channels.



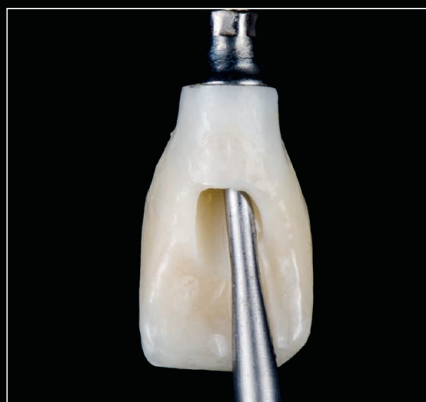5a



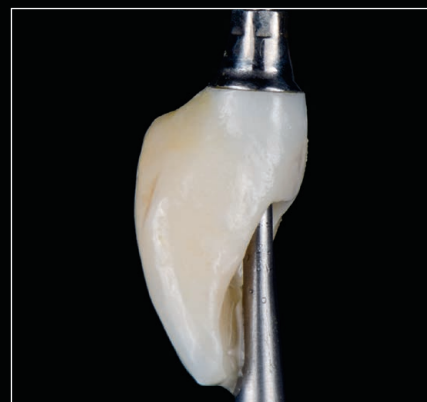5b



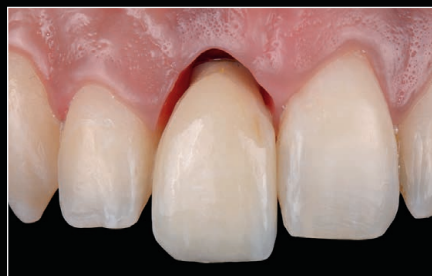6a



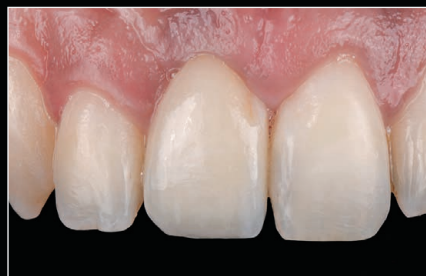6b



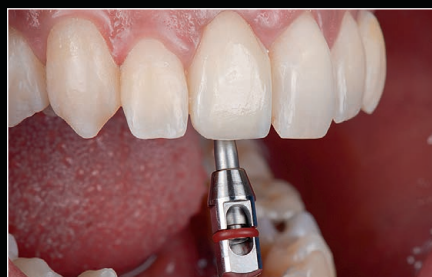6c



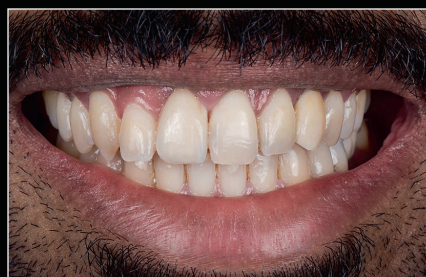7a



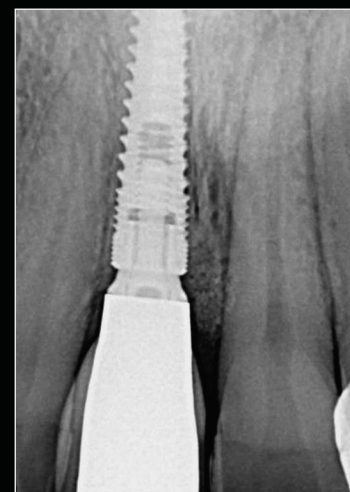
7b



7c



7d



8

**Figs 5a and 5b** Single implant placed with labial trajectory. Intraoral view and on the cast with the scan body in place.

**Figs 6a to 6c** Single-implant zirconia suprastructure with the titanium base luted.

**Figs 7a to 7d** Intraoral views of the single implant shown in Fig 6 delivered. Note the change in location of screw access to the cingulum area of the restoration.

**Fig 8** Radiographic view postinsertion of the single-implant restoration.

smaller and limit preloads to the restoration-implant complex. In addition, pre-angled screw-retained restorations are not available in all implant systems. The dynamic abutment for CAD/CAM use is available for many systems, and for most systems the screws can be torqued to 30 N/cm; where screw diameter is limited by the implant system, lower torques may be mandated (Figs 5 to 8). Using these abutments together with zirconia-based restorations addresses the most common biomechanical and biologic issues mentioned above.

## FULL-CONTOUR ZIRCONIA FOR LARGE REHABILITATIONS

Zirconia exists in several allotropic forms. For fabrication of dental restorations, the most desirable form is the tetragonal allotrope, as it has the physical and optical properties to provide strength and esthetics. The resistance to fracture that zirconia exhibits comes from a process known as transformation toughening. This process occurs as a result of allotropic change from the tetragonal to the monolithic form, which is 25% larger volumetrically than the tetragonal allotrope. The monolithic allotrope is the most stable form at room temperature; therefore, any energy applied to the material will cause this allotropic change, which in turn causes a volumetric change. This volumetric change in the adjacent areas of the crack prevents the crack from propagating.<sup>17,18</sup> In the literature that describes the clinical use of layered zirconia restorations, chipping of the veneering porcelain has been reported to be up to 50%. However, few of the zirconia substructure frameworks have been reported to fail, and those few failures were found to be caused by poor design, largely due to insufficient bulk of material in connector areas for fixed partial dentures.<sup>19,20</sup>

Implant-supported reconstructions fabricated from monolithic zirconia have the potential to be very durable because the weak link of veneering porcelain is removed from any areas with occlusal function. In addition, implant-supported structures have dimensions that are usually much larger than tooth-supported restorations and allow a much larger volume of material.<sup>21,22</sup> This results in eliminating areas of weakness of monolithic zirconia implant-supported screw-retained restorations. Together with excellent biocompatibility, good optical properties for tooth replacement, and ease of fabrication, zirconia should be considered as an attractive material to restore dental implants.

## CASE PRESENTATIONS

The following case presentations demonstrate in more detail how the combination of optical and physical properties of monolithic zirconia together with the ability to redirect screw access can help to provide patients with durable and esthetic restorations that can be easily maintained.

### Case 1

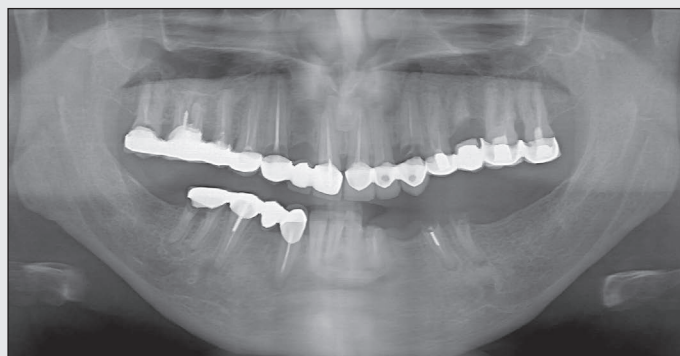
This patient presented with failing restorations, multiple periapical radiolucencies, and missing teeth. Thorough clinical examination, conventional two-dimensional radiography, and three-dimensional cone beam tomography were conducted (Fig 9).

The treatment plan involved extraction of all remaining dentition and replacement with implant-supported full-arch monolithic zirconia restorations. Analysis of the available bone determined that it would be appropriate to immediately load the implants postplacement. The ultimate design of the prosthesis was made using 3Shape software, with which tooth shape, size, and anatomy were selected and arranged virtually to mill a monolithic zirconia restoration.

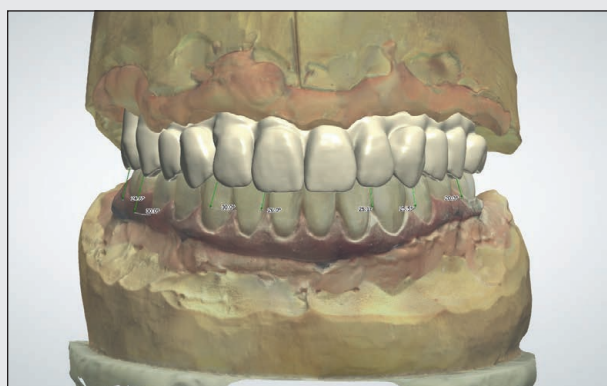Implant angulations were corrected using the dynamic abutments to allow screw accesses to exit in appropriate positions. Some screw accesses were redirected up to 30 degrees palatally, as they were placed following the presenting bony anatomy. The simulated soft tissue areas were designed and cut back to allow for soft tissue-colored ceramics to be layered.

The design was milled on a Weiland Hybrid machine using Zenostar Blank (T0 25 mm). After the soft milling process, the monolithic zirconia was sintered in a 9-hour cycle to effect the allotropic change to the tetragonal form of zirconia. Pink ceramics were layered, and teeth were surface characterized, glazed, and then polished to produce a natural luster. The Dynamic abutment titanium bases were cemented into the zirconia structures with Multilink HO (Ivoclar Vivadent) in the laboratory using the verified master cast as index, after which the occlusion was verified. Cementation of the bases into the zirconia framework serves several purposes. For one, it compensates for any distortions caused by the fabrication process—the process of sintering, where the allotropic transformation causes a 25% volumetric shrinkage that would be most causal of a misfit. When the bases are

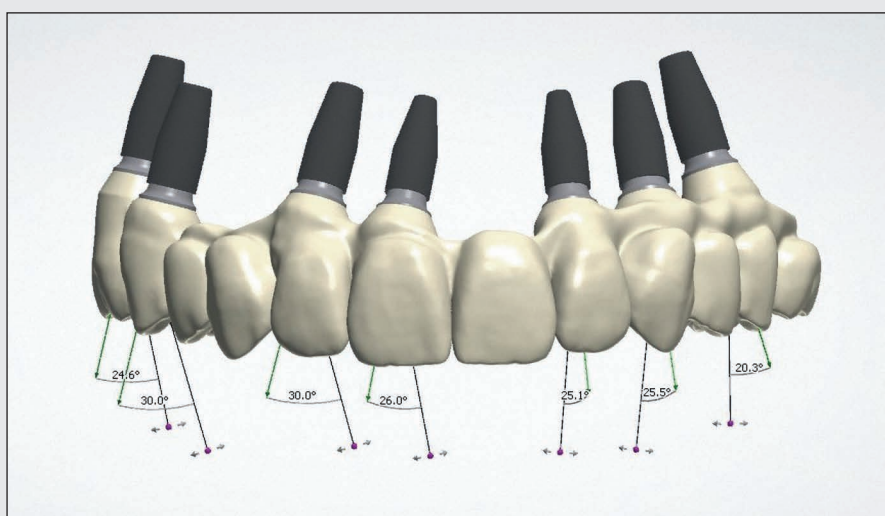
## CASE 1



**Fig 9** Preoperative radiograph. Note the extensive recurrent caries in the roots of all remaining teeth.



**10a**

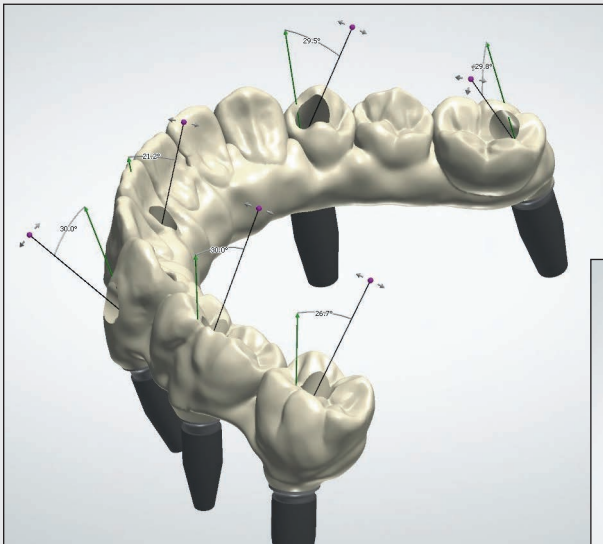


**10b**

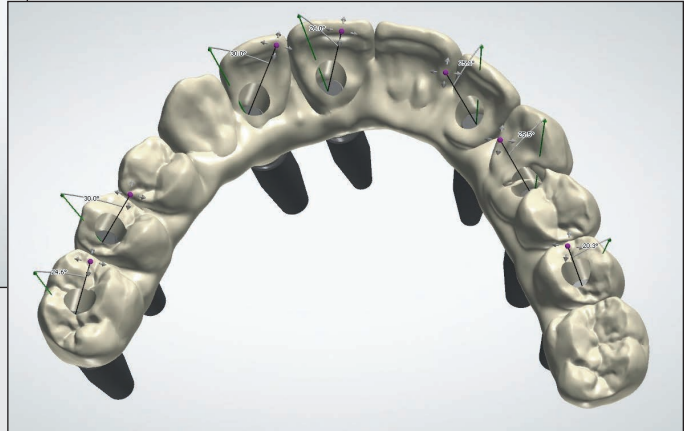
cemented using a verified master cast, all deviations can be compensated.<sup>23–28</sup> Upon delivery of the prostheses, the

screws were torqued based on the manufacturer's recommendations (Figs 10 to 14).

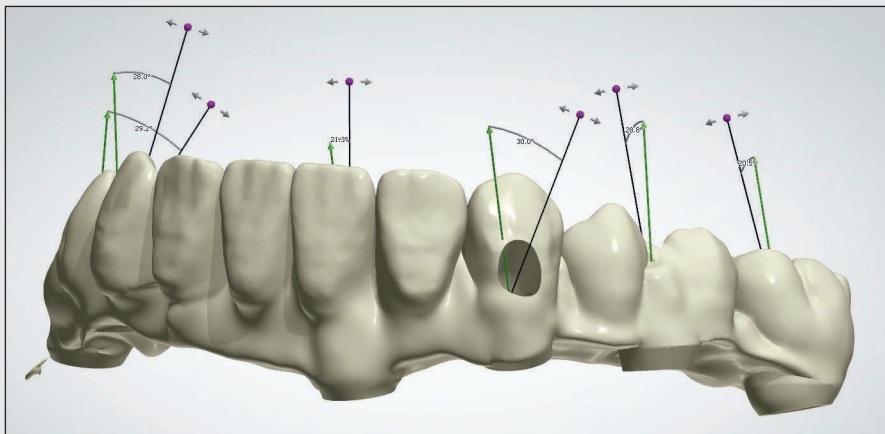




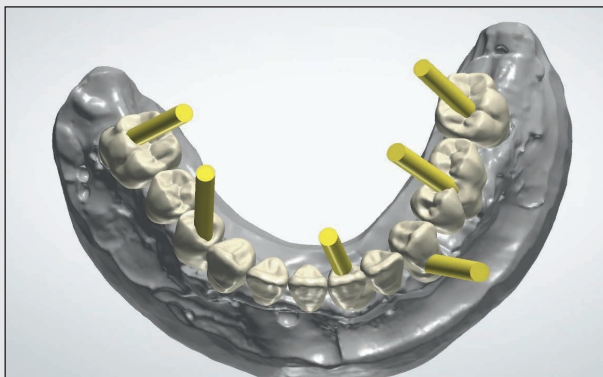
10c



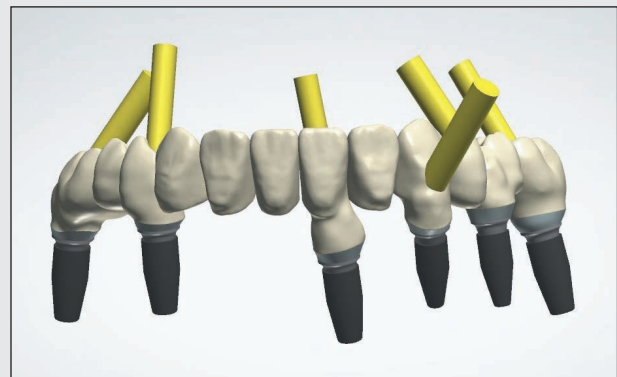
10d



10e



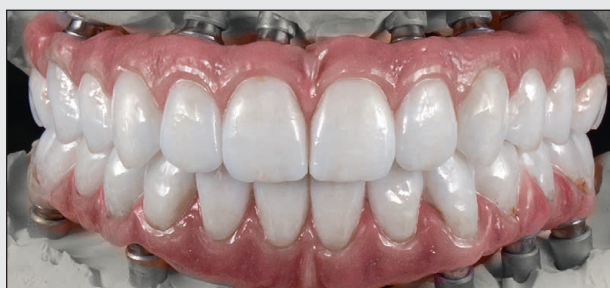10f



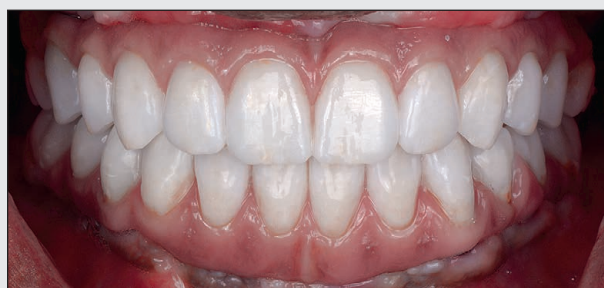10g

**Figs 10a to 10g** The CAD phase for both the maxilla and the mandible. The full-contour anatomy has cutback in areas to allow application of pink ceramics to simulate soft tissues.

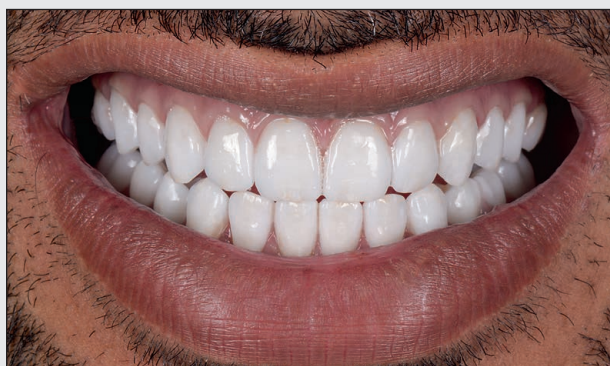



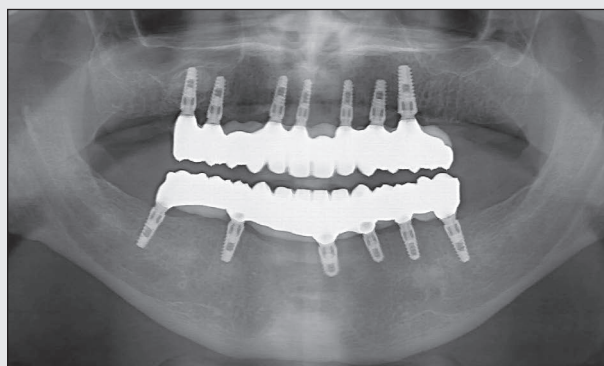
11



12



13



14

**Fig 11** Completed prostheses shown extraorally in occlusion.

**Fig 12** Intraoral view immediately after delivery.

**Fig 13** Tooth display in smile.

**Fig 14** Postoperative radiograph.

## Case 2

The second patient presented with failing restorations and implants. The remaining dentition was carious and mobile (Figs 15a to 15d).

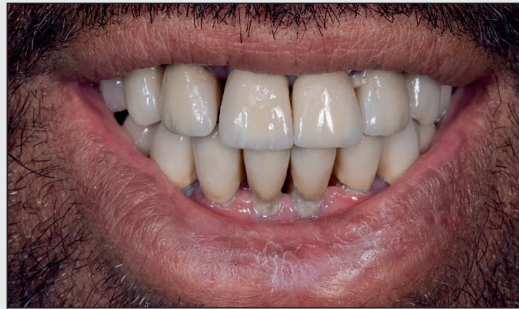After careful examination of the patient and the prognosis of the remaining teeth and implants, the definitive treatment plan dictated removal of the remaining teeth and failing implants. Following these extractions, implants were placed to support full-arch maxillary and mandibular fixed prostheses. Due to the bony anatomy of the patient, which was adversely affected by prior dental disease, the implants had to be inclined facially in order to be fully supported by bone. This provided good primary stability, which would allow implants to be loaded 24 hours postplacement (Figs 16a and 16b).

The provisional restoration that is delivered 24 hours later provides immediate improvement in esthetics and

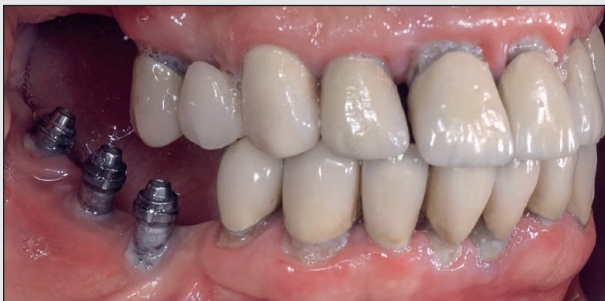function for the patient and allows the clinician and patient to evaluate parameters of esthetics and function. The same STL (Standard Tessellation Language) file utilized to fabricate the immediately loaded prosthesis was used to mill the definitive screw-retained full-contour zirconia frame, thus saving tremendous time and effort.

Figures 17 to 19 show the definitive prostheses made of full-contour zirconia except for the simulated soft tissue ceramics layered with porcelain. Note that the definitive prostheses milled in zirconia are almost exact replicas of the immediately loaded provisional restorations. The tooth form chosen from the library differs from that of the patient presented in case 1, as it provides a more masculine and strong character.<sup>29–31</sup> The zirconia restoration was manually polished after glazing to exhibit a more natural sheen and less glossy appearance.

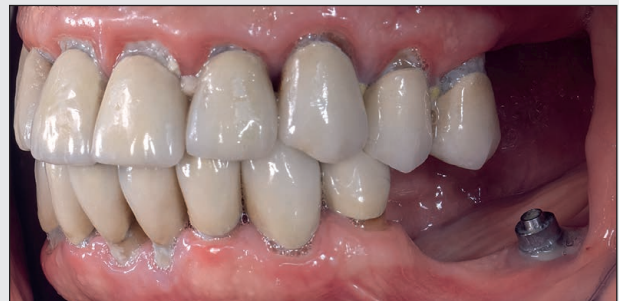## CASE 2



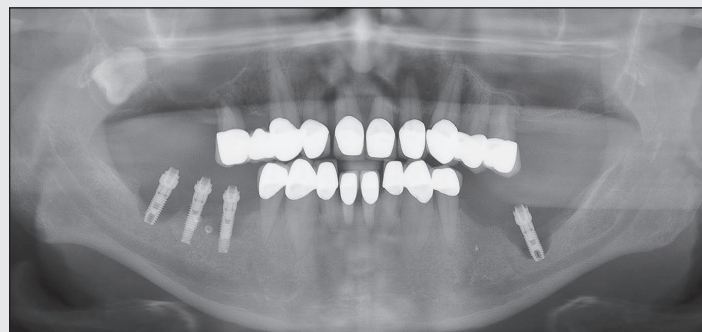
15a



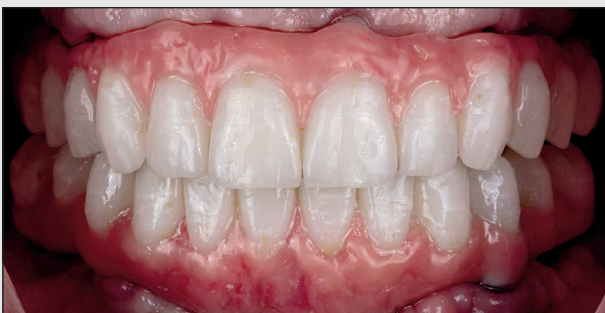15b



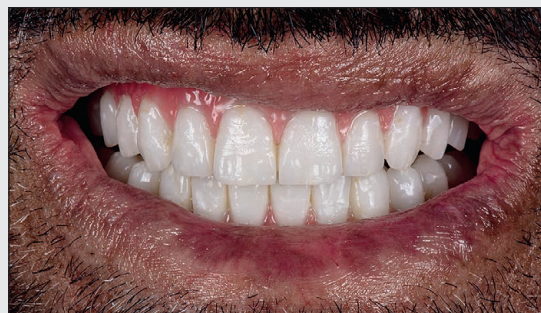15c



15d



16a

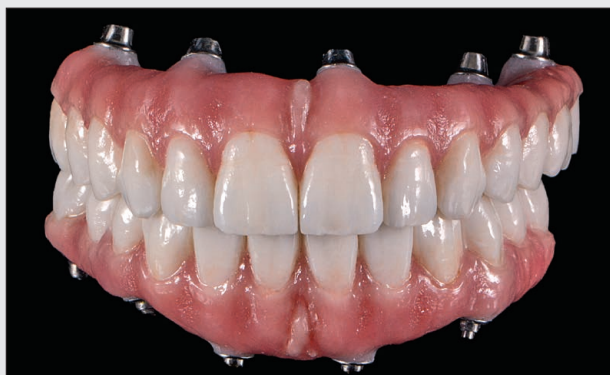

16b

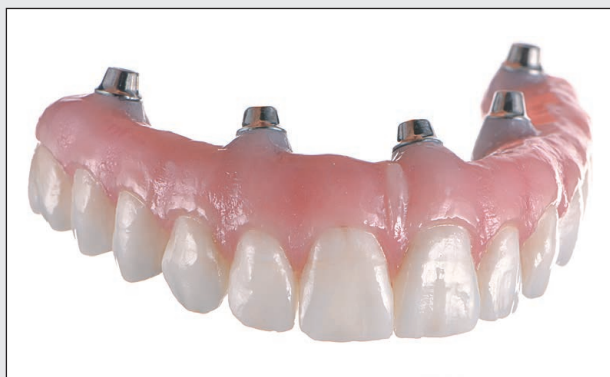**Figs 15a to 15d** Preoperative smile, intraoral lateral views, and radiograph.

**Figs 16a and 16b** Intraoral and smile views of immediately loaded prosthesis using polymethyl methacrylate that was screw retained.





17a

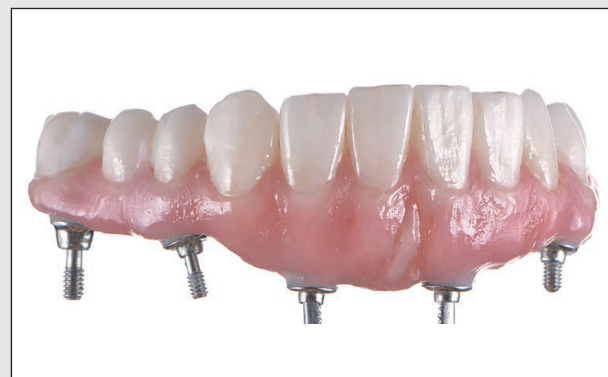

17b

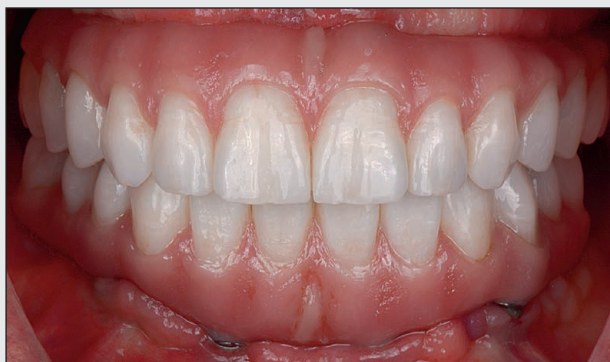**Figs 17a to 17c** Definitive full-contour zirconia prostheses with layered pink ceramics.

**Figs 18a and 18b** Intraoral views.

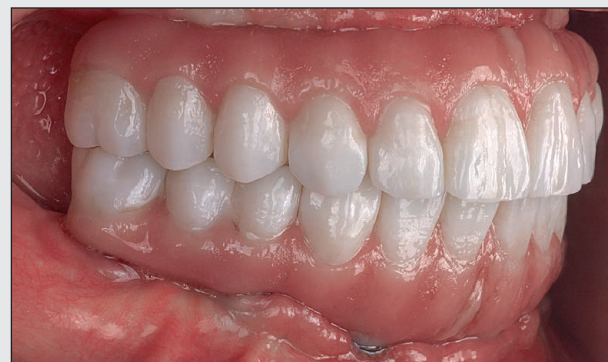**Fig 19** Postoperative radiograph.



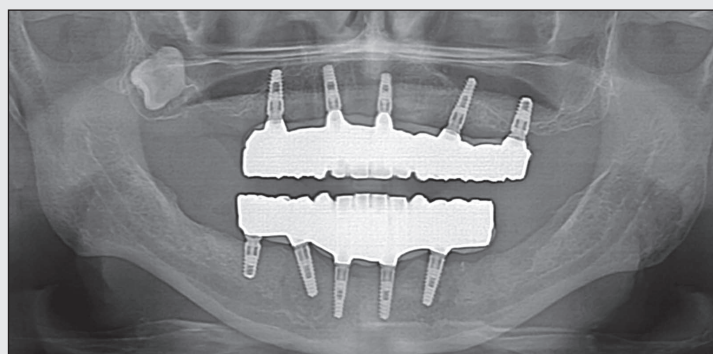
17c



18a



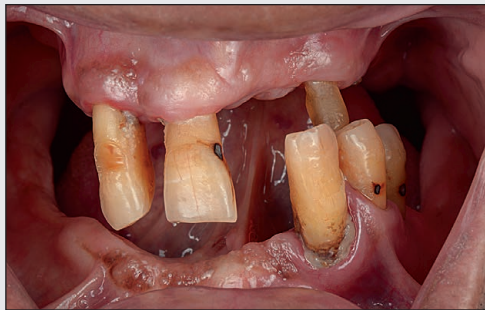18b



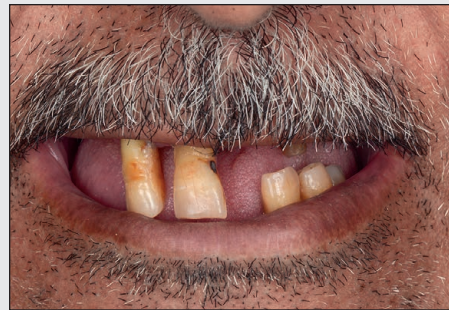19



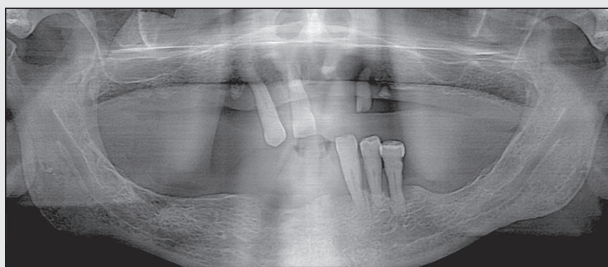
## CASE 3



20a



20b

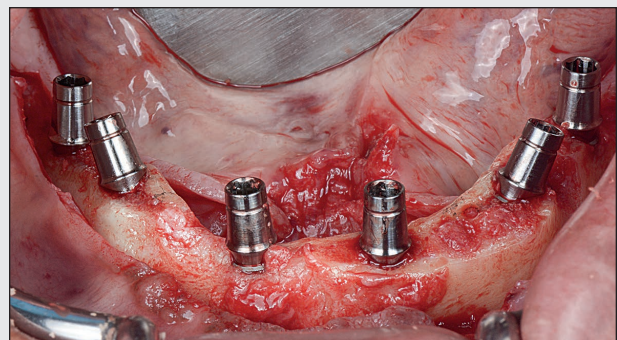


20c

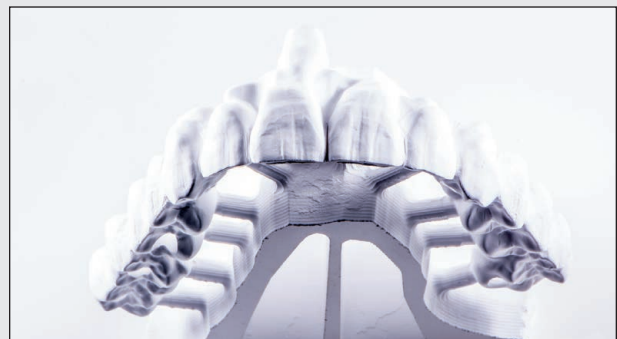**Figs 20a to 20c** Preoperative clinical and radiographic views of the patient. Note the pneumatized sinuses and the severe bone resorption in both arches.

**Fig 21** Six implants are placed with tilted positions to avoid the mental foramen and sinuses.

**Fig 22** Presintered full-contour zirconia framework is ready to be sintered for a 9-hour cycle.



21



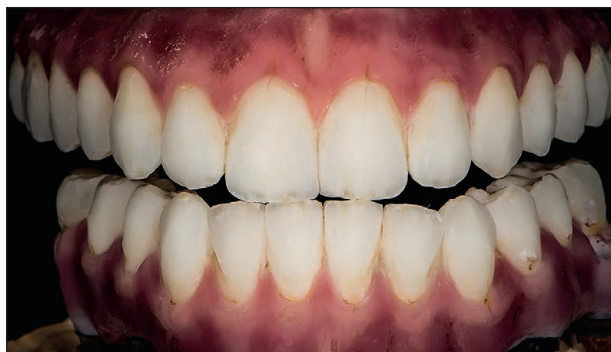22

### Case 3

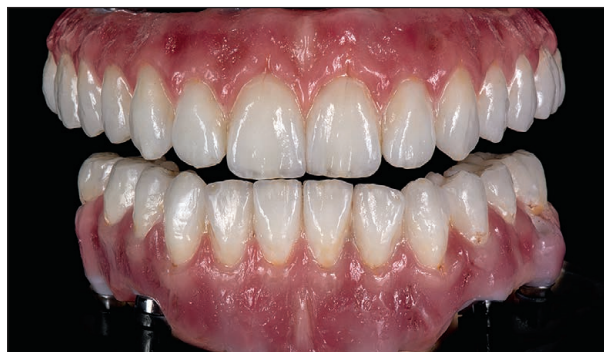The patient presented extensive tooth and tissue loss secondary to periodontal disease. In addition, the sinuses were pneumatized, further limiting implant positions (Figs 20a to 20c). Even with these anatomical limitations, six implants were placed in each arch without any grafting procedures. Tilting of the implants was required to avoid the sinus and mental foramen (Fig 21).

A similar protocol to the two previous treatments presented proceeded, except that the screw accesses were tilted medially due to the angulation of the implants. Be-

cause of the severity of bone resorption in the mandible, a 35-mm-thick zirconia blank (puck) had to be utilized for milling the full-contour framework. The dimensions of the anticipated restoration must be taken into account for a full-contour milled prosthesis, as many machines are not capable of accepting large blanks. Additionally, these soft milled (milled in the monoclinic phase) structures will shrink approximately 25% after sintering, which is the process of transformation of the monoclinic to tetragonal form that is desired for dental restorations. This would allow a maximum occlusal gingival dimension of 35 mm × 0.75, yielding approximately 26 mm (Figs 22 to 32).



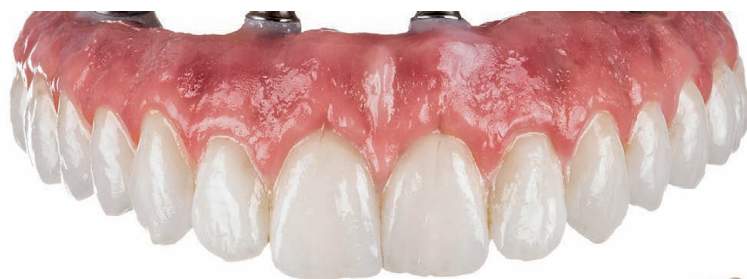**Fig 23** Polarized image removing any specular reflection showing the surface characterization performed in various areas to give the restoration a natural appearance. Note the blue and white highlights on the incisal edges to give the illusion of translucency, also the brown/ochre on the cervical areas.



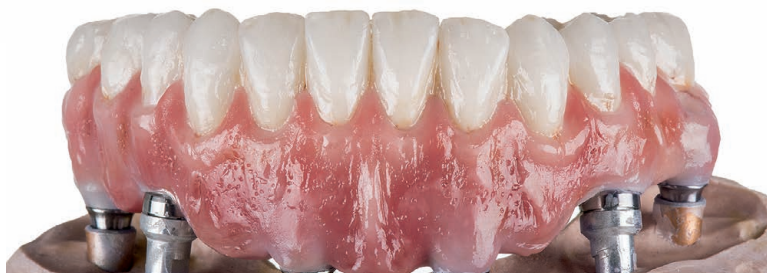**Fig 24** Full-contour zirconia with layered pink ceramics. Photograph taken without polarization.



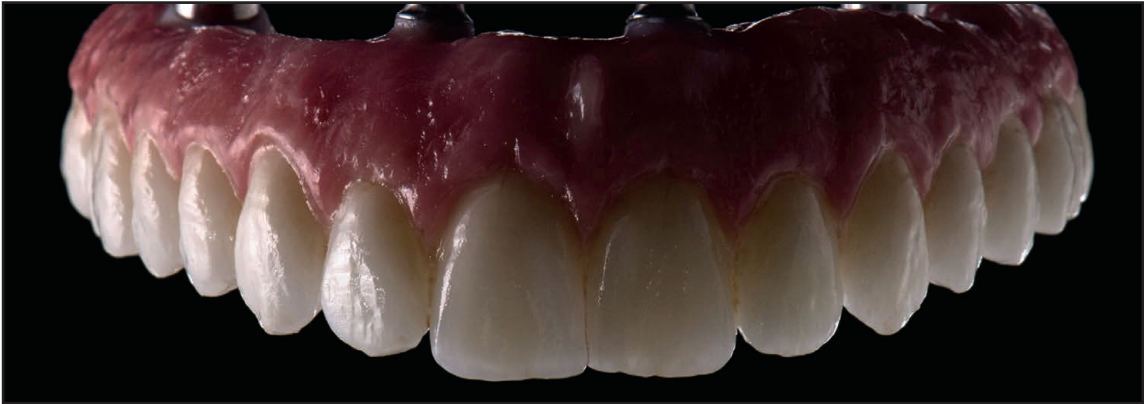**Figs 25a and 25b** Silver powder coating is used to show the detail that can be obtained from milling.



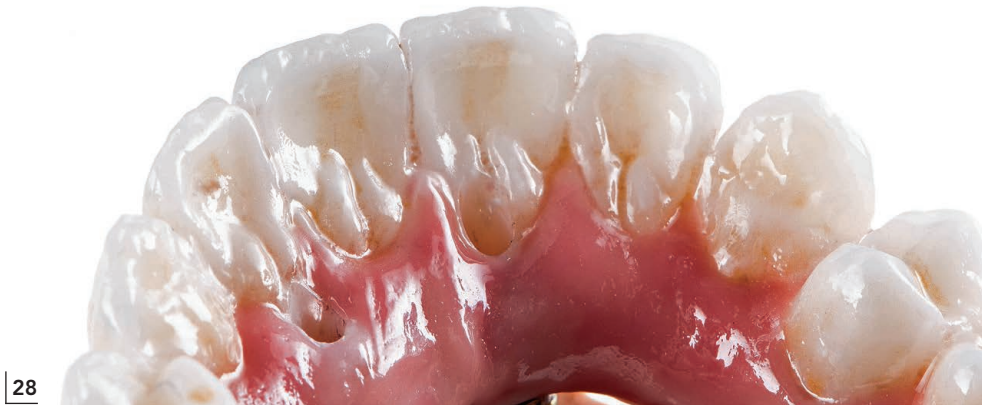**Figs 26a and 26b** Extraoral view of restorations. Note the vertical height of the mandibular prosthesis.







27



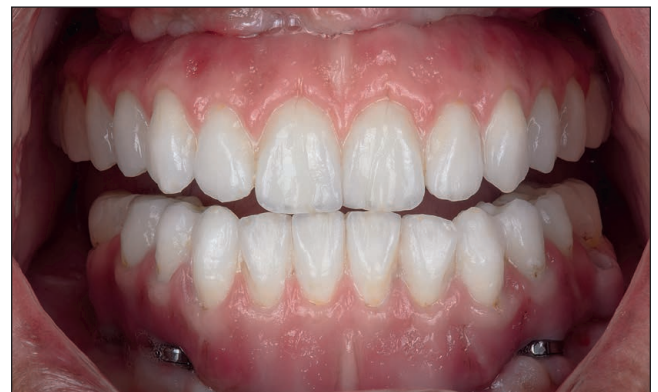28

**Fig 27** Natural texture obtained from milling and manual polishing.

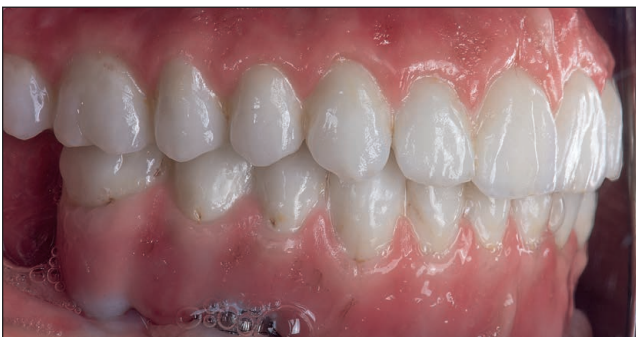**Fig 28** Lingual anatomy detail obtained by the milling process.

**Fig 29** Intraoral view of prostheses with incisors in edge-to-edge position.

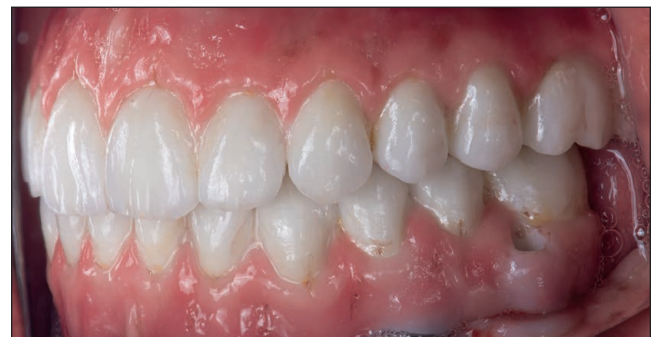**Figs 30a and 30b** Lateral views in occlusion.



29

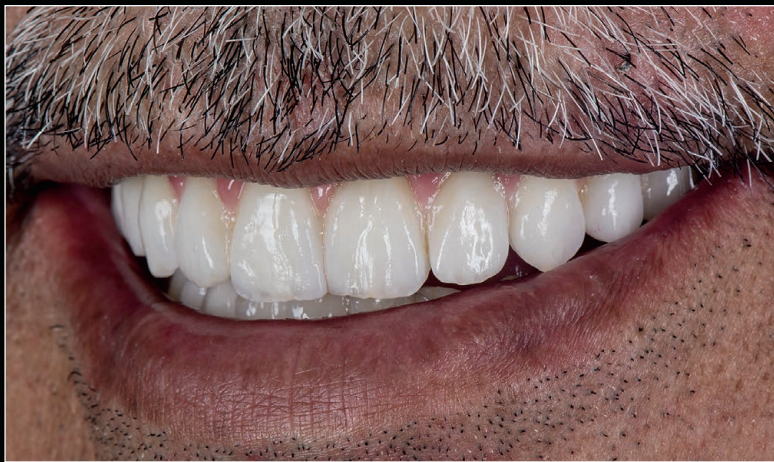

30a



30b

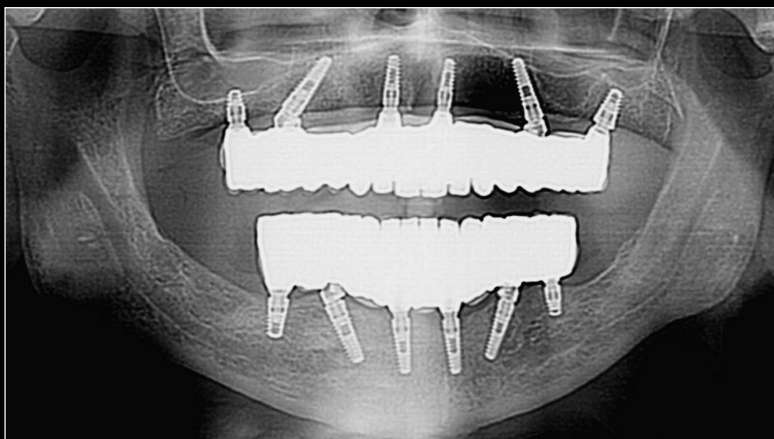




31a



31b



32

**Figs 31a and 31b** Postoperative smile.

**Fig 32** Postoperative radiograph. Note how the tilted implants avoid the sinus and mental foramina.

## CONCLUSIONS

Full-arch restorations can be fabricated with metal frameworks layered with acrylic, porcelain fused to metal, or more commonly as of late, zirconia that can be monolithic or layered with feldspathic porcelain. The esthetics and durability of acrylic prostheses are not optimal. Porcelain-fused-to-metal restorations are often fabricated in segments to facilitate porcelain application and fit of the restorations to implants. The individual segments can be removed and repaired should there be issues of porcelain breakage. The need for restoring full arches with segments causes more implants to be placed compared to a restoration that can be fabricated to fit precisely across the arch, such as titanium frameworks layered with acrylic or zirconia-based restorations with cemented bases. With implant-supported restorations, porcelain fracture or chipping is a common and difficult problem to manage, more so with large restorative structures. The use of monolithic zirconia restorations for these large reconstructions eliminates the use of feldspathic porcelains and allows the restoration to be fabricated in one piece as described above.<sup>23,24</sup> The use of full-arch restorations also allows fewer implants to be placed due to splinting across the arch, which results in a biomechanically advantageous loading pattern for the retaining screws and the implants.<sup>32,33</sup>

The combination of being able to redirect screw access relative to the axis of an implant together with the ability to use CAD/CAM to manufacture monolithic zirconia restorations can be a solution for the most common complications when implant-supported restorations are provided.

## REFERENCES

1. Chee W, Jivraj S. Screw versus cemented implant supported restorations. *Br Dent J* 2006;201:501–507.
2. Chee W, Felton DA, Johnson PF, Sullivan DY. Cemented versus screw-retained implant prostheses: Which is better? *Int J Oral Maxillofac Implants* 1999;14:137–141.
3. Chee WW, Torbati A, Albouy JP. Retrievable cemented implant restorations. *J Prosthodont* 1998;7:120–125.
4. Gervais MJ, Wilson PR. A rationale for retrievability of fixed, implant-supported prostheses: A complication-based analysis. *Int J Prosthodont* 2007;20:13–24.
5. Korsch M, Obst U, Walther W. Cement-associated peri-implantitis: A retrospective clinical observational study of fixed implant-supported restorations using a methacrylate cement. *Clin Oral Implants Res* 2013;25:797–802.
6. Korsch M, Robra BP, Walther W. Cement-associated signs of inflammation: Retrospective analysis of the effect of excess cement on peri-implant tissue. *Int J Prosthodont* 2015;28:11–18.
7. Korsch M, Robra BP, Walther W. Predictors of excess cement and tissue response to fixed implant-supported dentures after cementation. *Clin Implant Dent Relat Res* 2015;17(suppl 1):e45–e53.
8. Wilson TG Jr. The positive relationship between excess cement and peri-implant disease: A prospective clinical endoscopic study. *J Periodontol* 2009;80:1388–1392.
9. Agar JR, Cameron SM, Hughbanks JC, Parker MH. Cement removal from restorations luted to titanium abutments with simulated subgingival margins. *J Prosthet Dent* 1997;78:43–47.
10. Linkevicius T, Puisys A, Vindasiute E, Linkeviciene L, Apse P. Does residual cement around implant-supported restorations cause peri-implant disease? A retrospective case analysis. *Clin Oral Implants Res* 2013;24:1179–1184.
11. Linkevicius T, Vindasiute E, Puisys A, Peculiene V. The influence of margin location on the amount of undetected cement excess after delivery of cement-retained implant restorations. *Clin Oral Implants Res* 2011;22:1379–1384.
12. Misawa M, Lindhe J, Araújo MG. The alveolar process following single-tooth extraction: A study of maxillary incisor and premolar sites in man. *Clin Oral Implants Res* 2016;27:884–889.
13. Chappuis V, Engel O, Reyes M, Shahim K, Nolte LP, Buser D. Ridge alterations post-extraction in the esthetic zone: A 3D analysis with CBCT. *J Dent Res* 2013;92(12 suppl):195S–201S.
14. Chappuis V, Engel O, Shahim K, Reyes M, Katsaros C, Buser D. Soft tissue alterations in esthetic postextraction sites: A 3-dimensional analysis. *J Dent Res* 2015;94(9 suppl):187S–193S.
15. Lam RV. Contour changes of the alveolar processes following extractions. *J Prosthet Dent* 1960;10:25–32.
16. Araújo MG, Lindhe J. Dimensional ridge alterations following tooth extraction. An experimental study in the dog. *J Clin Periodontol* 2005;32:212–218.
17. Kelly JR, Denry I. Stabilized zirconia as a structural ceramic: An overview. *Dent Mater* 2008;24:289–298.
18. Denry I, Kelly JR. State of the art of zirconia for dental applications. *Dent Mater* 2008;24:299–307.
19. Koenig V, Vanheusden AJ, Le Goff SO, Mainjot AK. Clinical risk factors related to failures with zirconia-based restorations: An up to 9-year retrospective study. *J Dent* 2013;41:1164–1174.
20. Guess PC, Att W, Strub JR. Zirconia in fixed implant prosthodontics. *Clin Implant Dent Relat Res* 2012;14:633–645.
21. Venezia P, Torsello F, Cavalcanti R, D'Amato S. Retrospective analysis of 26 complete-arch implant-supported monolithic zirconia prostheses with feldspathic porcelain veneering limited to the facial surface. *J Prosthet Dent* 2015;114:506–512.
22. Larsson C, Vult Von Steyern P. Implant-supported full-arch zirconia-based mandibular fixed dental prostheses. Eight-year results from a clinical pilot study. *Acta Odontol Scand* 2013;71:1118–1122.
23. Al-Meraikhi H, Chee W, Takanashi T. An alternative to traditional implant-supported porcelain-fused-to-metal restorations. *Quintessence Dent Technol* 2014;37:113–124.

24. Goldberg J, Torbati A, Aalam AA, Chee W. Implant-supported full-arch zirconia fixed dental prostheses for the rehabilitation of a patient with a failing dentition. *Quintessence Dent Technol* 2016;39:179–196.
25. Yannikakis S, Prombonas A. Improving the fit of implant prosthetics: An in vitro study. *Int J Oral Maxillofac Implants* 2013;28:126–134.
26. Menini M, Pera F, Migliorati M, Pesce P, Pera P. Adhesive strength of the luting technique for passively fitting screw-retained implant-supported prostheses: An in vitro evaluation. *Int J Prosthodont* 2015;28:37–39.
27. Karl M, Taylor TD, Wichmann MG, Heckmann SM. In vivo stress behavior in cemented and screw-retained five-unit implant FPDs. *J Prosthodont* 2006;15:20–24.
28. McCartney JW, Doud R. Passive adaptation of the prosthesis-implant interface by soldering gold cylinders to the framework casting. *J Prosthet Dent* 1993;70:17–20.
29. Frush JP, Fisher RD. Dentogenics: Its practical application. *J Prosthet Dent* 1959;9:914–921.
30. Frush JP, Fisher RD. How dentogenic restorations interpret the sex factor. *J Prosthet Dent* 1956;6:160–172.
31. Frush JP, Fisher RD. Introduction to dentogenic restorations. *J Prosthet Dent* 1955;5:586–590.
32. Rangert B, Jemt T, Jörneus L. Forces and moments on Brånemark implants. *Int J Oral Maxillofac Implants* 1989;4:241–247.
33. Mericske-Stern R, Worni A. Optimal number of oral implants for fixed reconstructions: A review of the literature. *Eur J Oral Implantol* 2014;7(suppl 2):S133–S153.