



TriLor Arch – James Davidge, JDT – May 2019

QUIZ ARTICLE

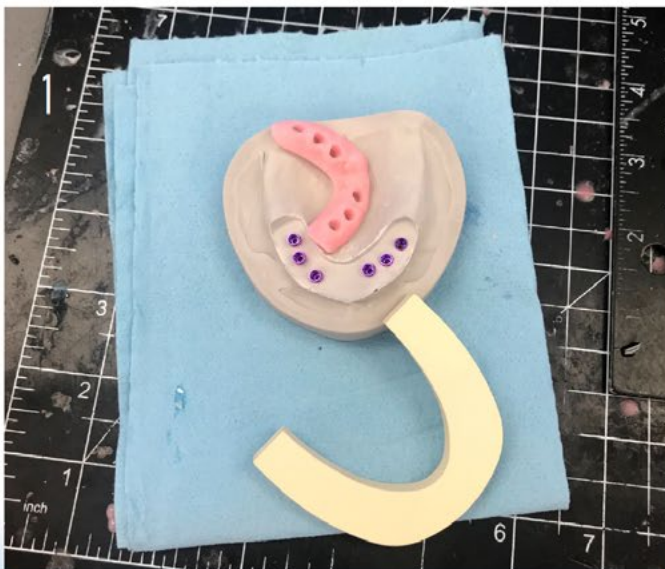JDT TECHNICAL

1/2 point CDT
documented
scientific credit.
See Page 30.

By James Davidge

Mission Accepted: The Four Day Hybrid Denture Restoration


I received a message from the restoring dentist that a case needed to be fabricated in the least amount of lab time possible, but quality, function, and esthetics could not be compromised. If we could save a few dollars in any other way, even better! Oh, and I was given four total days to deliver. It sounded like Mission Impossible; but I think we accomplished the goal. In this article, I'll share how I provided a hybrid denture restoration that met the dentist and patient's expectations of quality, function, and esthetics without compromising the budget in just four days.



The first appointment was on Monday and the dentist took a fixture level impression of the maxillary six implant arch to be restored with a (non-provisional) permanent fixed acrylic hybrid denture to be delivered four working days later.

On Monday, the soft tissue master cast (Fig. 1) was poured into the Anaxdent rim former with a split cast magnet placed in the former prior to the stone in the base. Once the model was completed, six non-engaging titanium temporary cylinders were seated in the implant analogs (Fig. 2).

TriLor from PREAT Corporation (Fig. 3) was chosen as the implant suprastructure material for this case. TriLor forms a covalent bond to acrylic or composite veneering material, providing a strong, lightweight, and aesthetic restoration and features a natural shock absorbing character (Fig. 4). With the prefabricated TriLor arch forms, I could fabricate the framework in



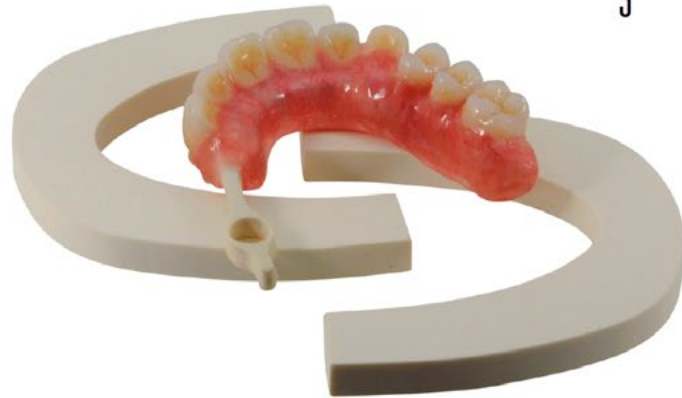2

minutes in my own laboratory, saving time and money while providing a lighter, strong restoration.

I chose the TriLor 5.5mm arch form for the strengthening and splinting component for the maxillary six implant fixed hybrid denture. I used baseplate wax over the Temp Cylinders on my cast, and transferred the position of the cylinders from the wax to the arch form. A small round bur was used to transfer the position.

Since I planned on using the TriLor arch form as my verification jig, I simply cut a hole for each cylinder to fit through with a 1mm/2.5mm ring space circumference around the diameter of each cylinder. After that, the TriLor arch was lightly sandblasted using aluminum oxide 50 pm/270 mesh on the inner wall and rim of the temp cylinder access hole created. The TI temp cylinders were sandblasted as well. After that simple preparation, the TriLor arch was primed with a light cure primer and gel and looted together. I used LukaFix made by LukaDent.

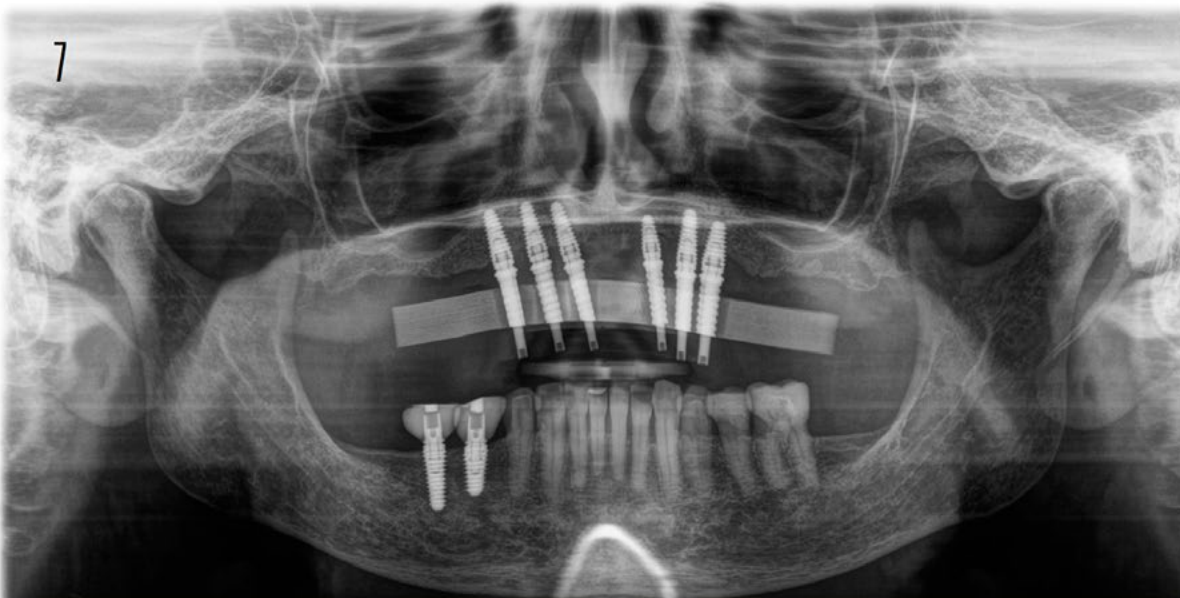
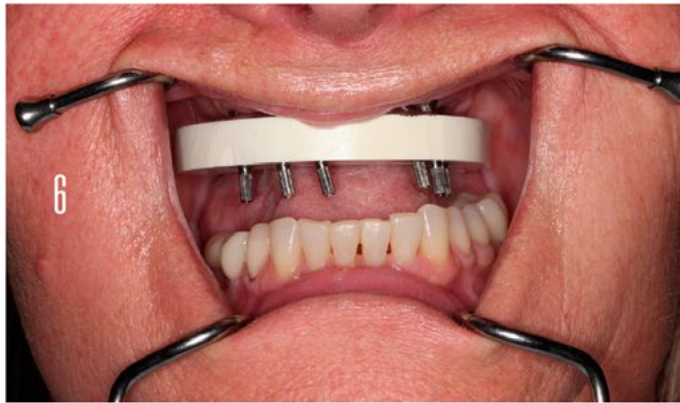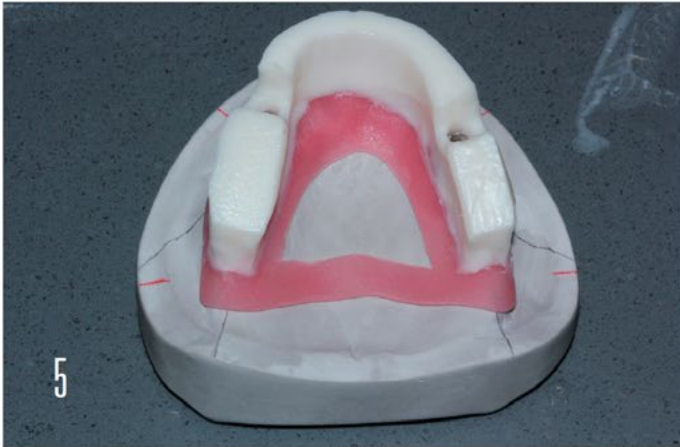
Next, an engaging record base and occlusal rim were made by adding two more temp cylinders to the master cast placed bilaterally right and left. Primo Pattern light cure resin base plate



3



4



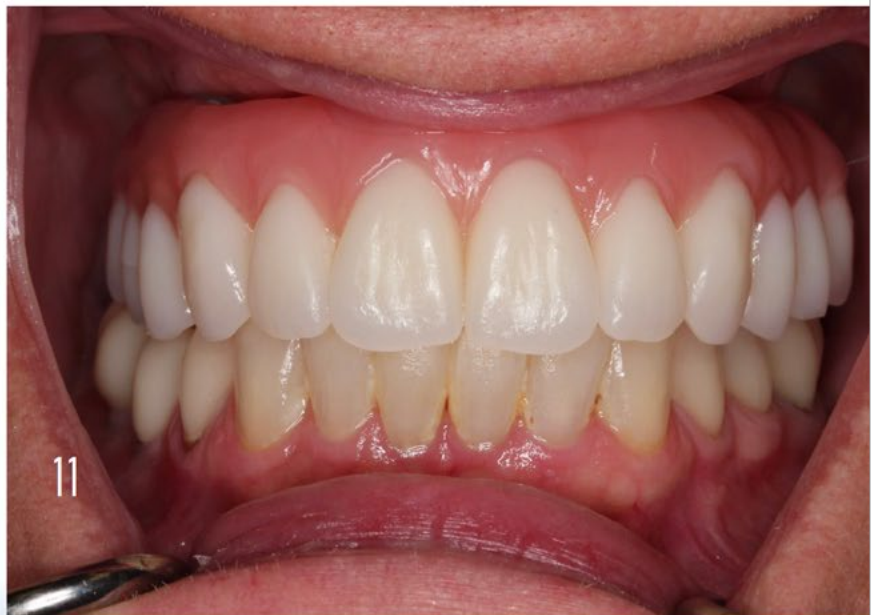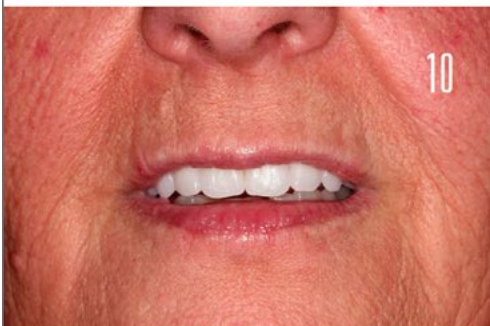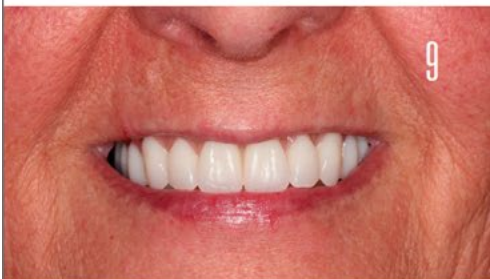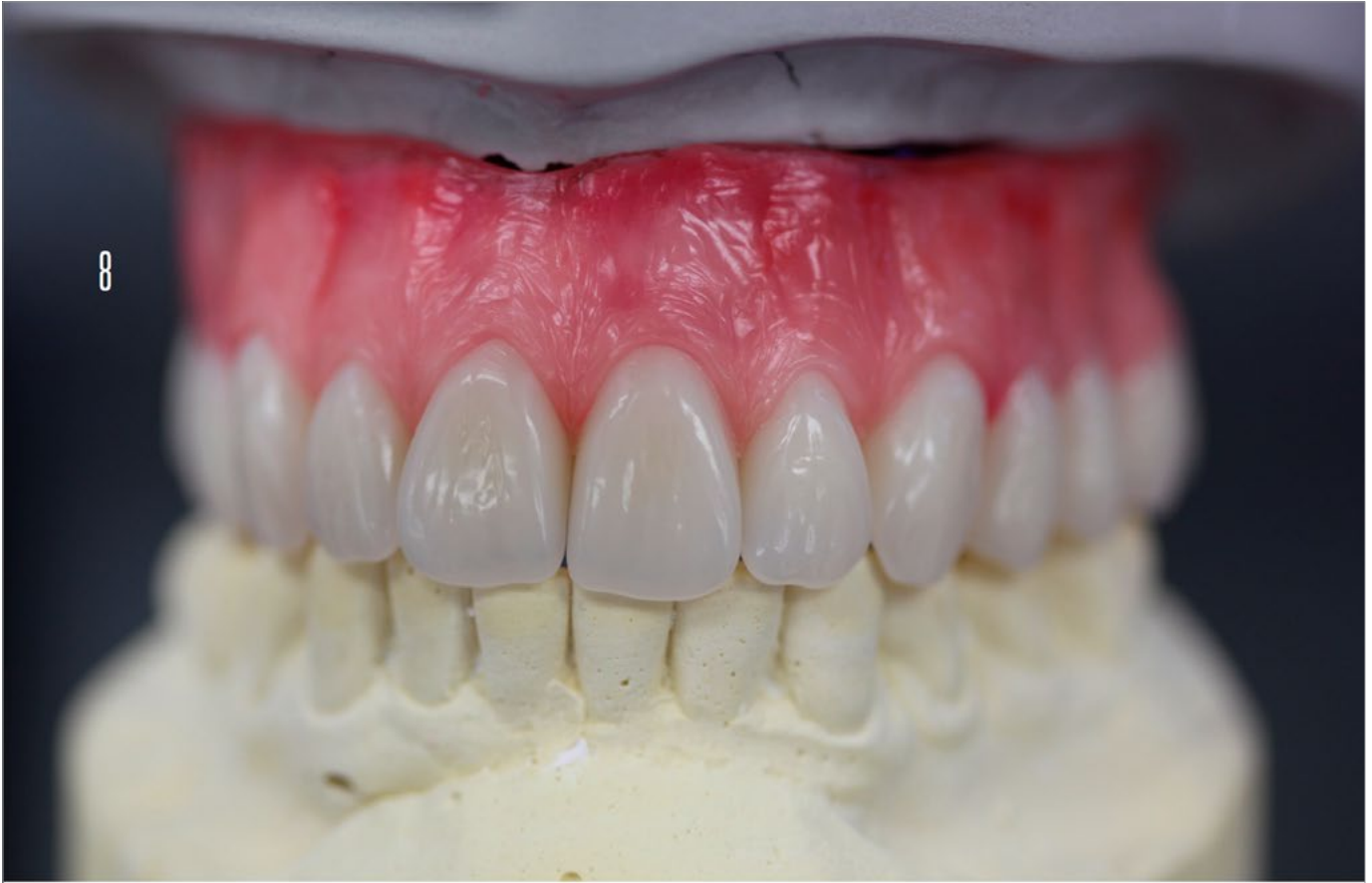material made by PrimoTech was fashioned into the functionally desired position (Fig. 5).

The patient was seen Tuesday morning. The TriLor verification jig was placed (Fig. 6) and a pano was taken which indicated the master cast was accurate (Fig. 7) and that a passive fit should be achieved. I did not alter the prefabricated TriLor arch form at this time. Another technique would have been to have my dentist pick up the temp cylinders chairside inside of the TriLor arch form, assuring a totally passive fit as well. After the verification jig was removed, the occlusal rim was engaged and the vertical dimension and provisional information was recorded.

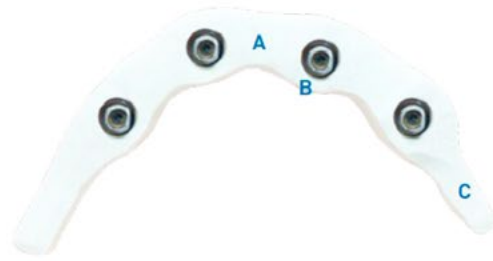
Later that day, the case was mounted on another split cast magnet placed on the bottom of the master cast. The Anaxdent pre-formed base of the cast was coated with a small amount of Vaseline and lightly flame torched to create a uniform surfaced separating agent so the plaster was able to engage the model as well as be removable without altering or damaging the model.

Once the models were split cast articulated, denture teeth were selected (Ivoclar Phonares II) and were set up in wax for a functional phonetic aesthetic try in (Fig. 8).

Wednesday morning, the patient tried the engaging based denture tooth waxed arrangement in for fit, form and function (Figs. 9-11).

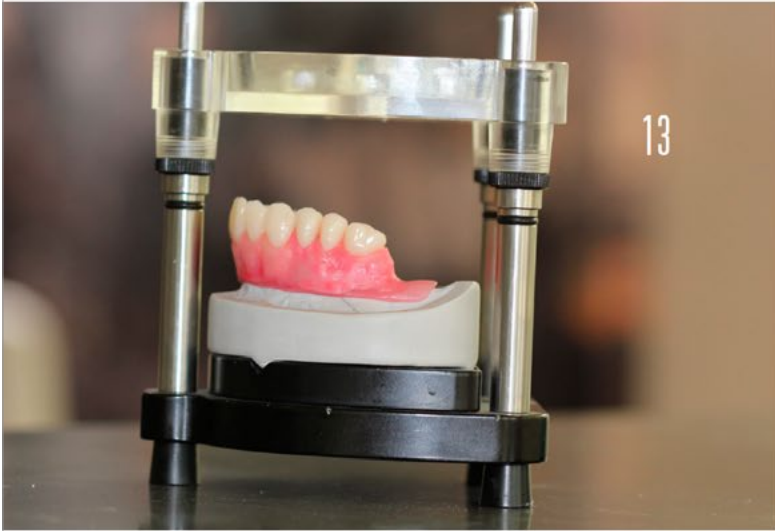

12



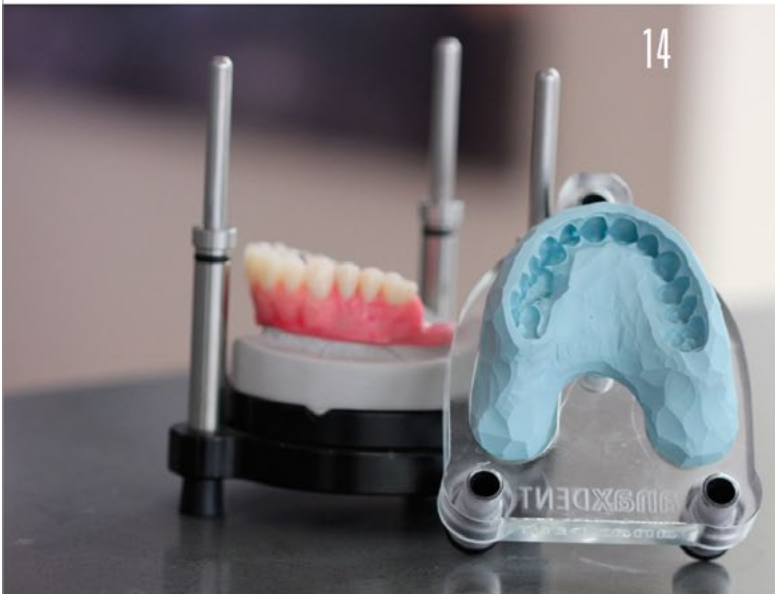After the patient and dentist approved the setup, I was ready for the TriLor verification jig to be formed to the individual dimensions dictated by the wax up as well as the material indications shown in Figure 12 (Fig. 12). (A) Ideally, we want 7mm² connections, (B) the minimal thickness around the cylinders is 0.8mm, and (C) the maximum cantilever is 10mm.

13




The master cast with the wax up engaged was placed into the Anexdent Verticator utilizing the indexed magnetically retained base for accuracy and stabilization (Fig. 13). A silicone putty matrix was formed around the wax up, engaging the top half of the verticator capturing tooth position and anatomical dimensions of the prostheses (Fig. 14). The silicone was then cut away 2mm above the gingival margin (Fig. 15). The engaging base plate was then removed and the denture teeth were boiled out, cleaned, and placed back into the matrix (Fig. 16). Next, the TriLor

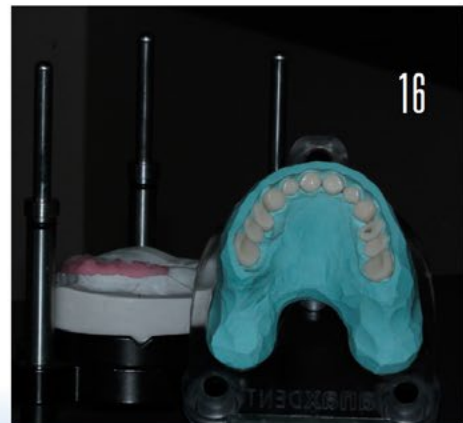
14

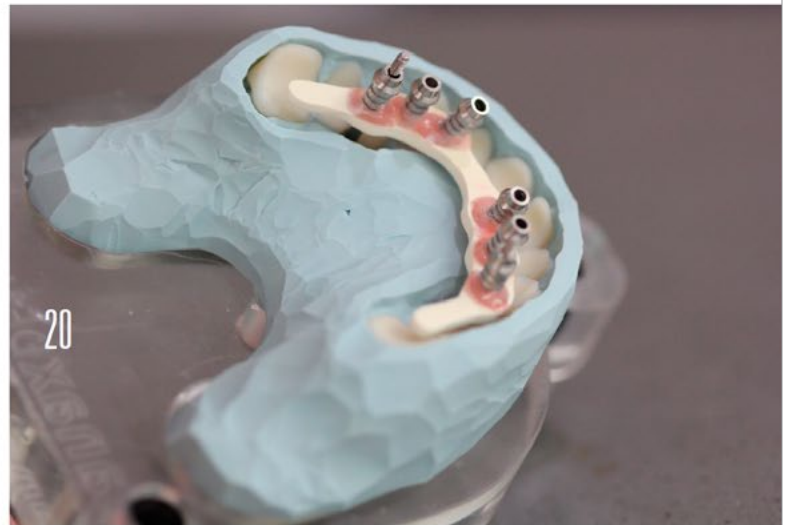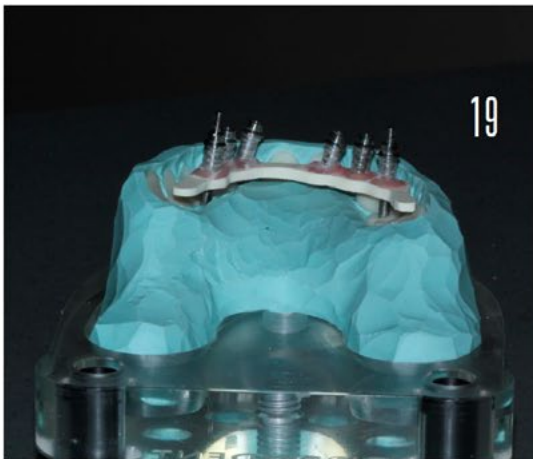

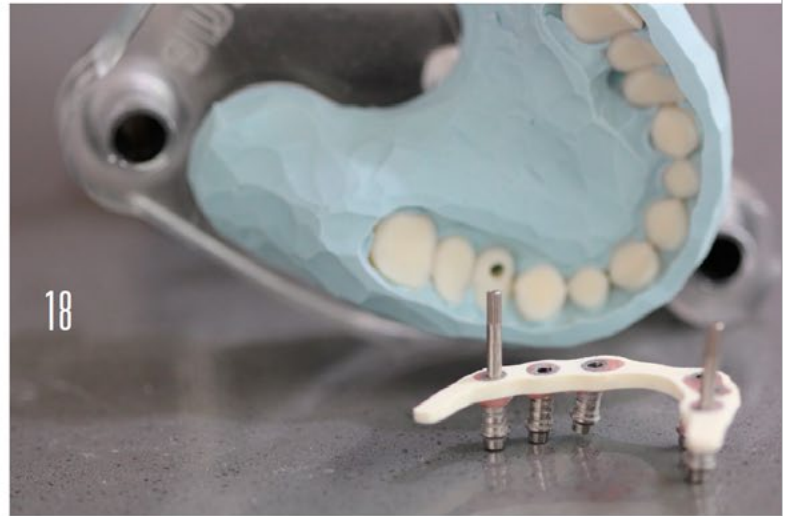
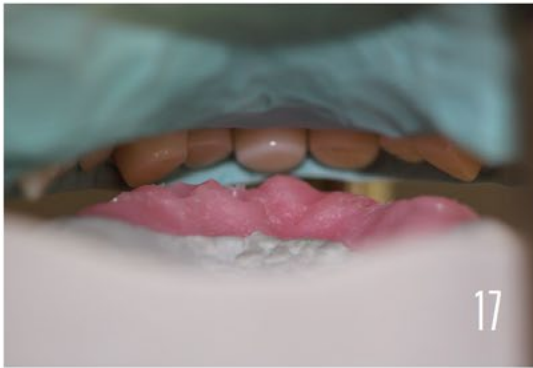15



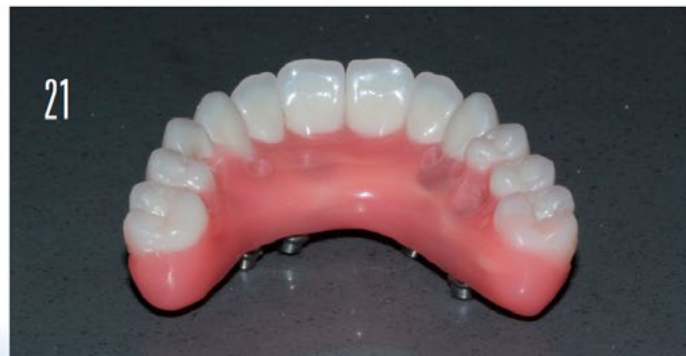16

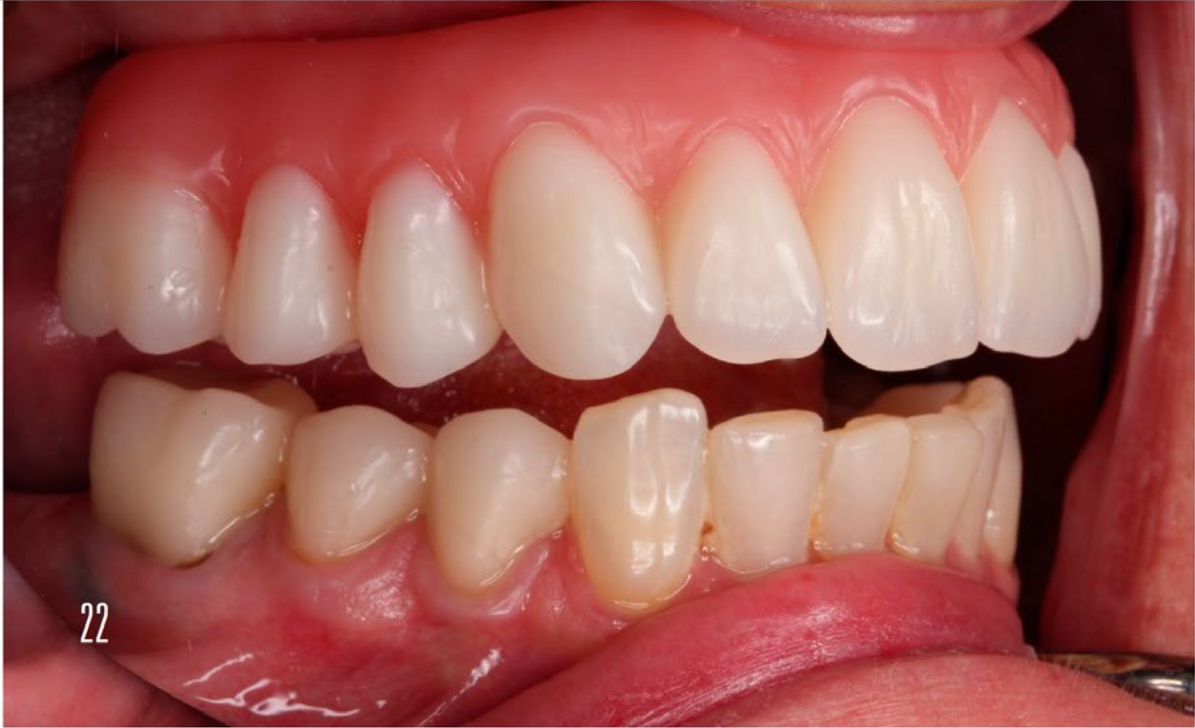



verification jig was placed onto the master cast with the denture teeth cleaned up and placed back in the matrix affixed to the top of the verticulaor. With the TriLor on the cast and denture teeth in the silicon, now the amount of space I had to work with could be seen from the basal portion of the denture teeth to the highest point of the TriLor as well as titanium temp cylinders (Fig. 17). A carbide burr was used to adjust the TriLor to the preformed arch in this specific case, allowing for an ideal 2.5mm of acrylic thickness (Fig. 18).

Thursday morning the case was invested into the Ivobase injection flask and processed conventionally (Fig. 19). Prior to injection, the only additional prep needed for the TriLor was a light sandblast then a coat of monomer to prime it for the acrylic processing (Fig. 20). The case was divested and ground to final dimensions and polished for delivery (Fig. 21).





Davidge

Friday morning the permanent screw retained hybrid was delivered without a hiccup. The advantage to the patient and dentist was a very fast workflow from start to finish without a compromise in the prostheses strength or integrity as well as an overall very lightweight finished product (Fig. 22).

The advantage to the lab was the ability to keep the bar in-house and have control of every aspect of the design and fabrication/alteration process without needing third party communication to complete that huge step in any fixed hybrid restoration; not to mention the cost savings as compared to outsourcing a TI milled bar. There was no need to opaqued the TriLor as its tooth color didn't show through the regular pink monochromatic non-opaqued

acrylic used in this case. The biggest advantage of this material and casework flow process for me and my lab--even with the big cost savings considered--has to be the TIME saved in the process in comparison to a conventionally outsourced TI milled bar. My discretion is the deciding factor as to how much time it takes to complete the case, not factors outside of my control. **JDT**

About the Author

James Davidge has over 10 years of experience in the dental industry, beginning his career as a technician at Great White Dental Lab in Santa Maria, California where he also held a management position. In 2013, James opened his own lab, Dental Works West in Arroyo Grande, California.

QUIZ

Receive .5 point documented scientific credit for passing a quiz about this article. To get the quiz go to www.nadl.org/jdt. You can enter your answers to this quiz (course code #37613 at www.nadl.org/members/JDT/quizzes/index.cfm or fax the completed quiz to (850) 222-0053. This quiz is provided to test the technician's comprehension of the article's content and does not necessarily serve as an endorsement of the content by NADL or NBC.

